

9. Bundeskongress der Niedergelassenen Chirurgen
2.- 4. März 2007 in Nürnberg



Finger- /Fußnagelchirurgie

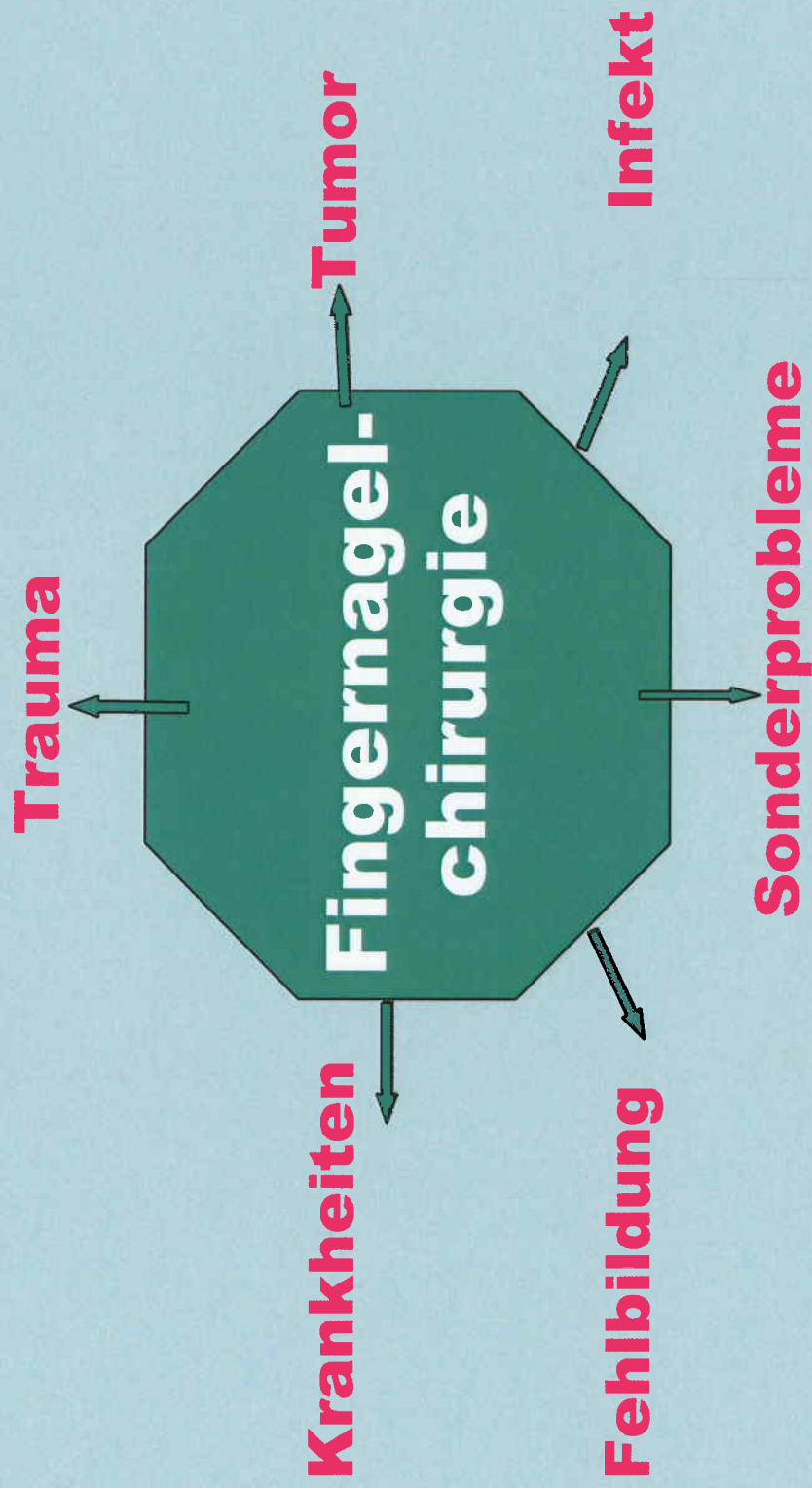
Dr. med. Alfred AJ Gruber, Nürnberg



RTZ Nürnberg
Ihr Partner für Gesundheit, Schönheit & Wohlbefinden



DIAH e.V.

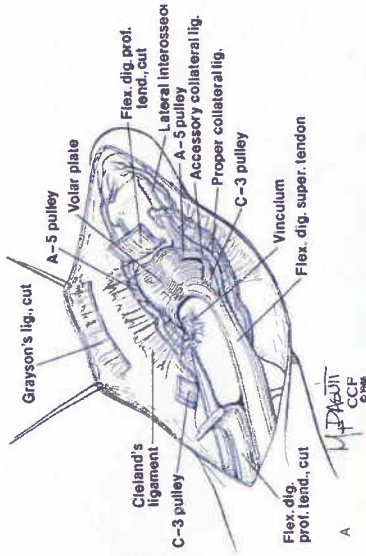


RTZ Nürnberg
Ihr Partner für Gesundheit, Schönheit & Wohlbefinden

Dr. A. Gruber

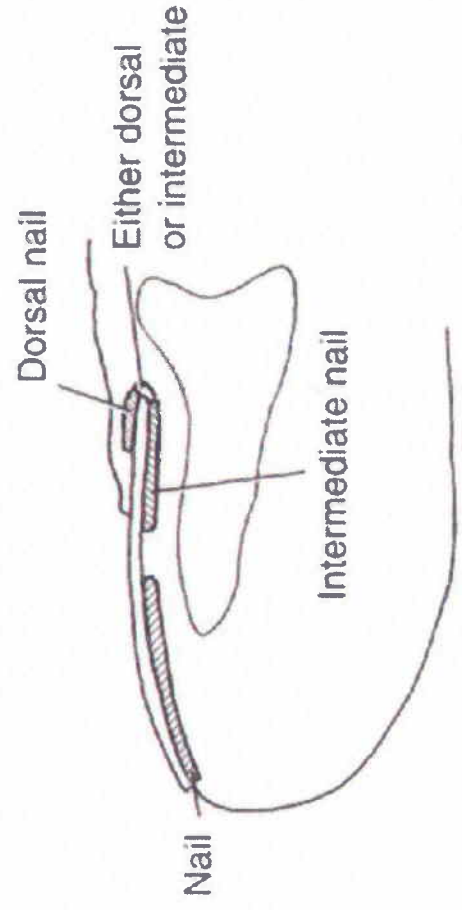
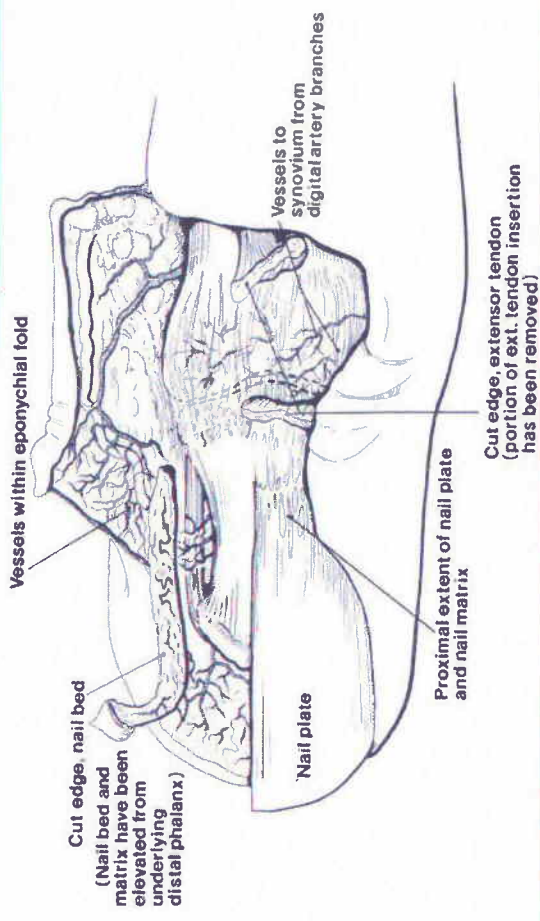
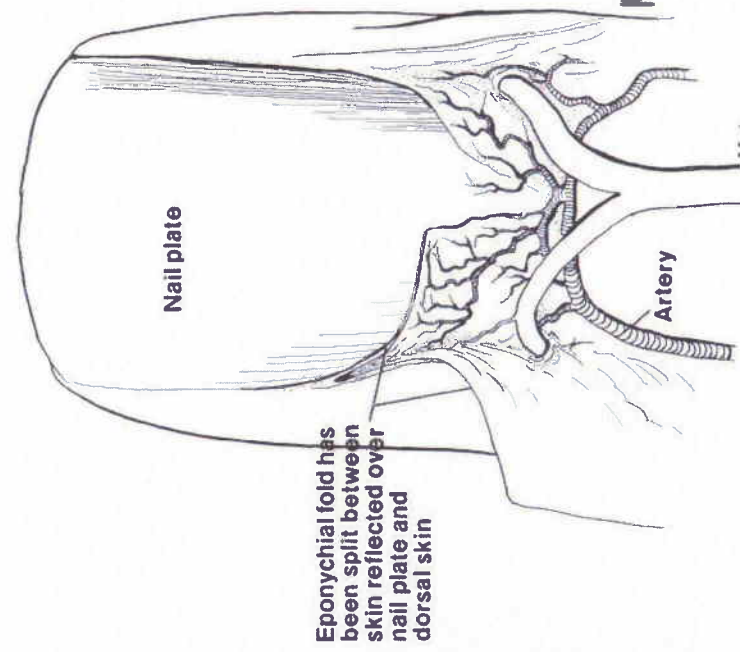
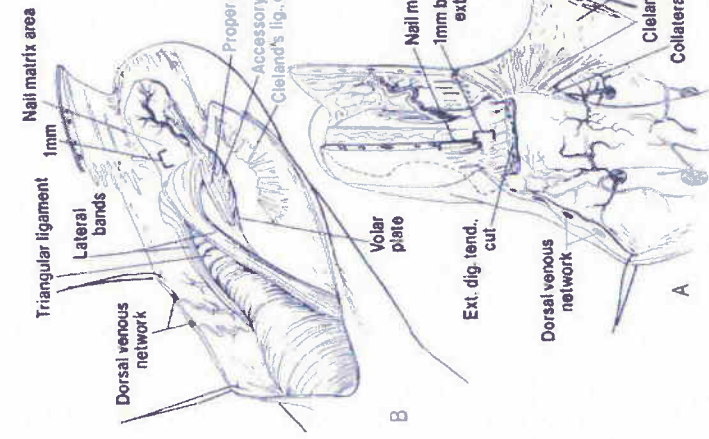


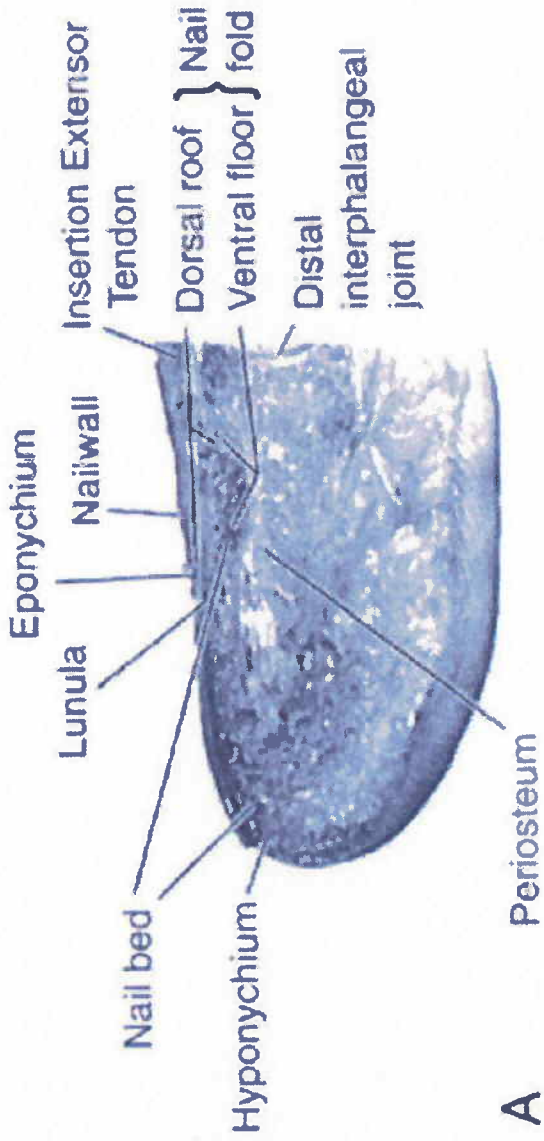
DIAH e.V.



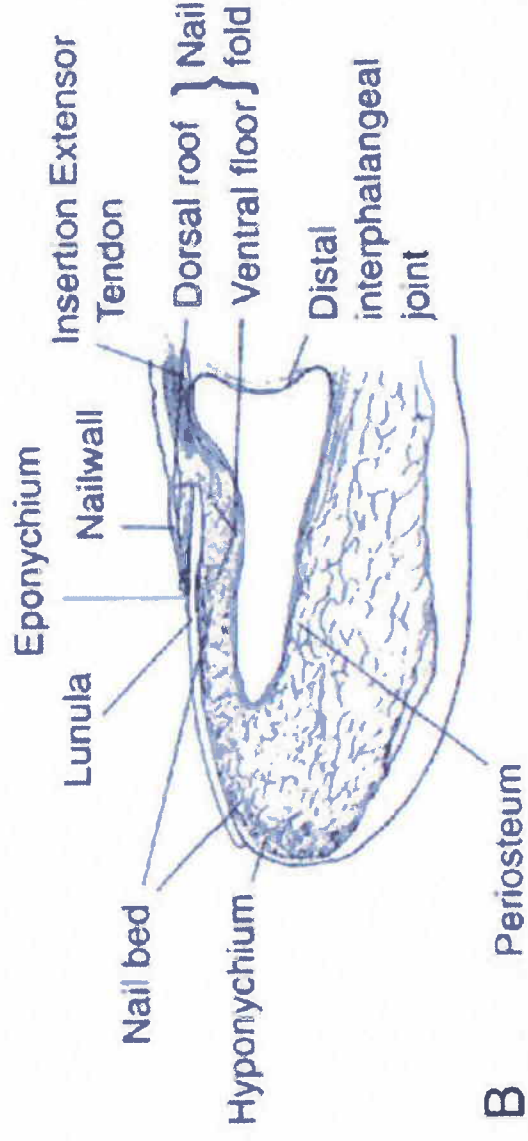
Nagel Anatomie

M. P. ASBUTT
CCF
© 1986



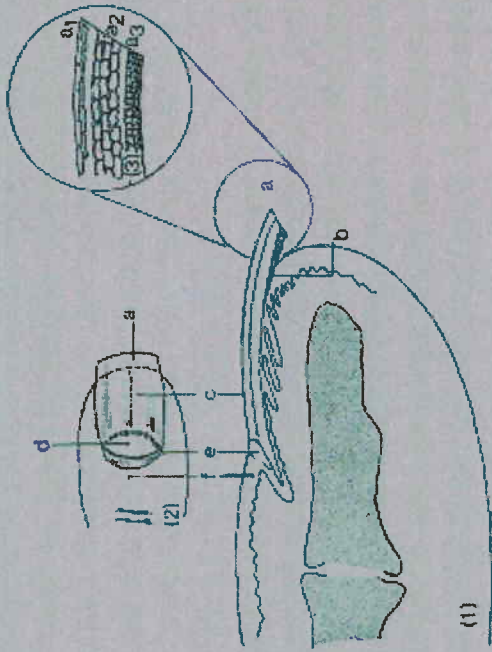


A



B





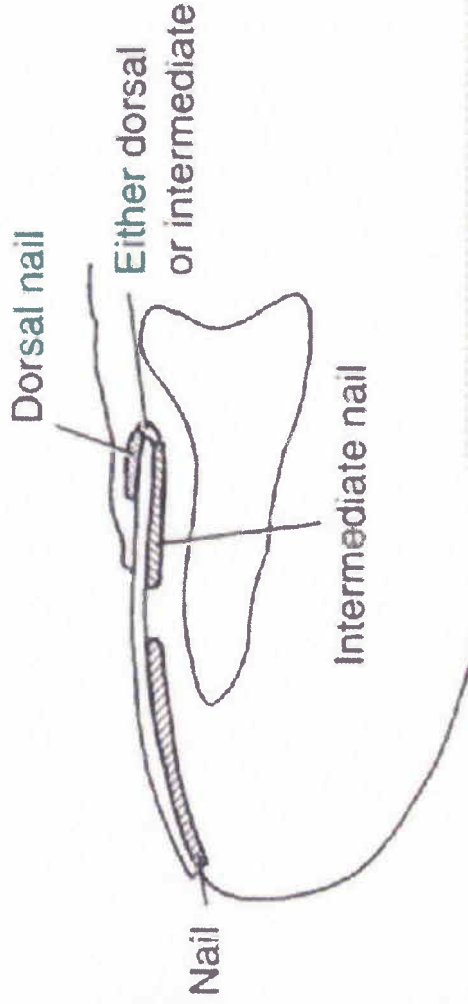
1) Längsschnitt

- a) freier Nagelrand
- b) Hyponychium
- c) Nagelplatte
- d) Lunula
- e) Cuticula
- f) dorsaler Nagelfalz

3) Schichtaufbau des freien Nagelteils

- a.) Dorsalnagel
- a.) Intermediäriemagel
- a.) Ventralnagel

Die Areale der Nagelproduktion im Nagelbett



RTZ Nürnberg
Ihr Partner für Gesundheit, Schönheit & Wohlbefinden

Dr. A. Gruber



DIAH e.V.

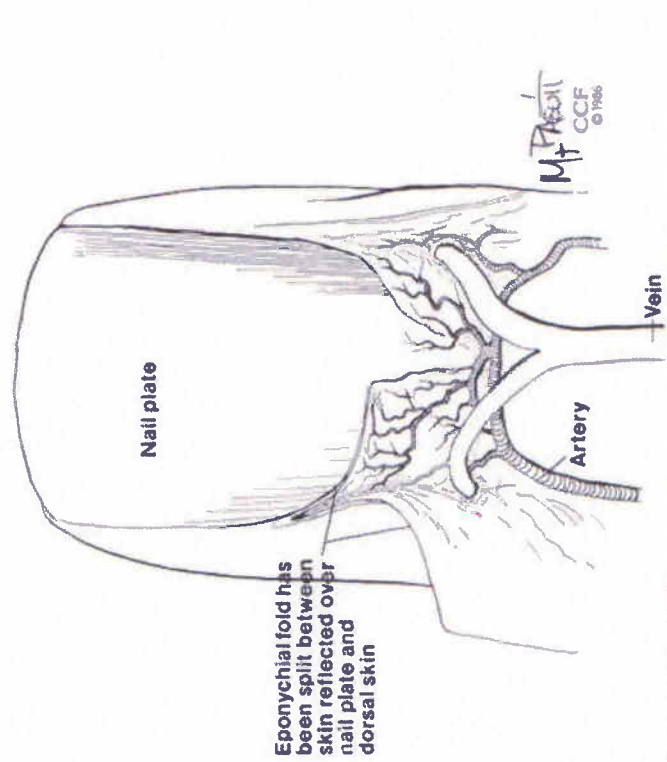
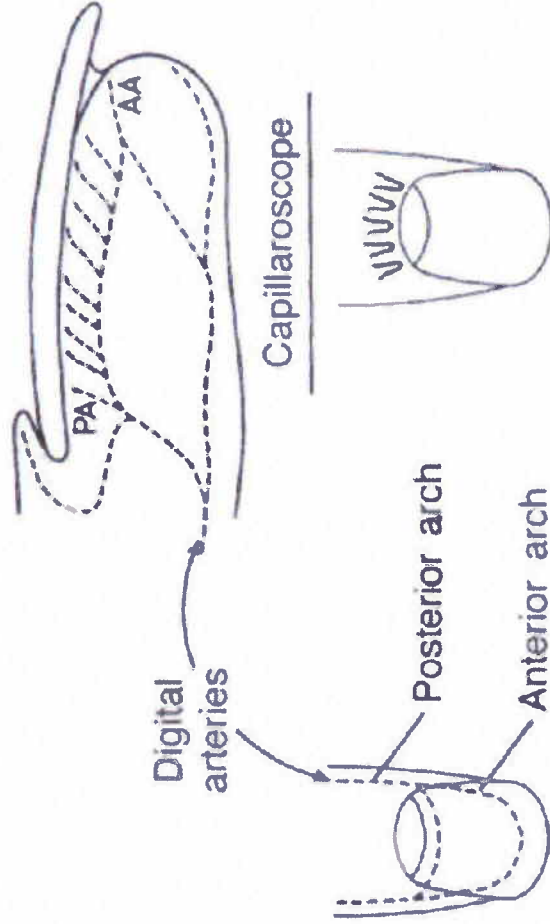
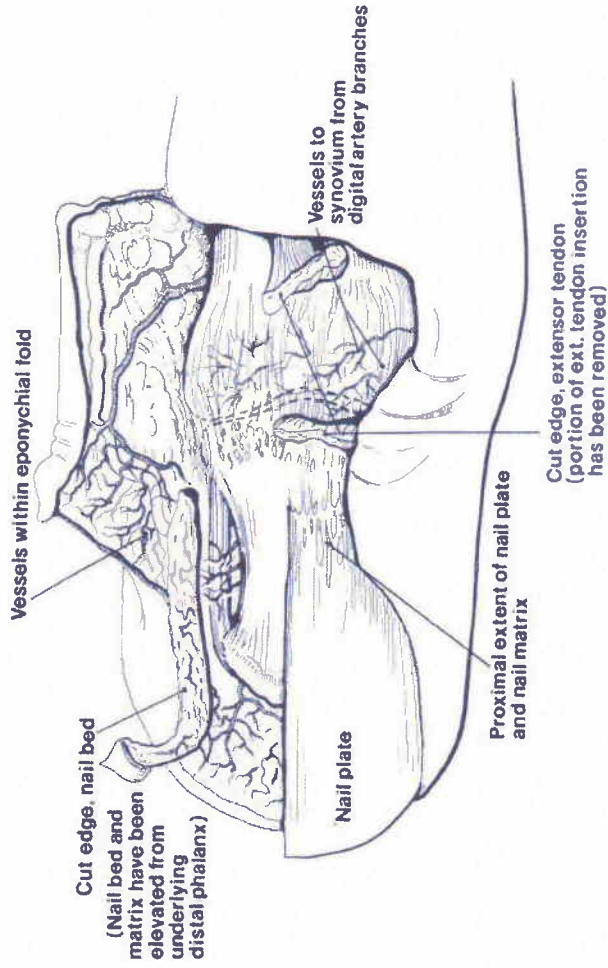
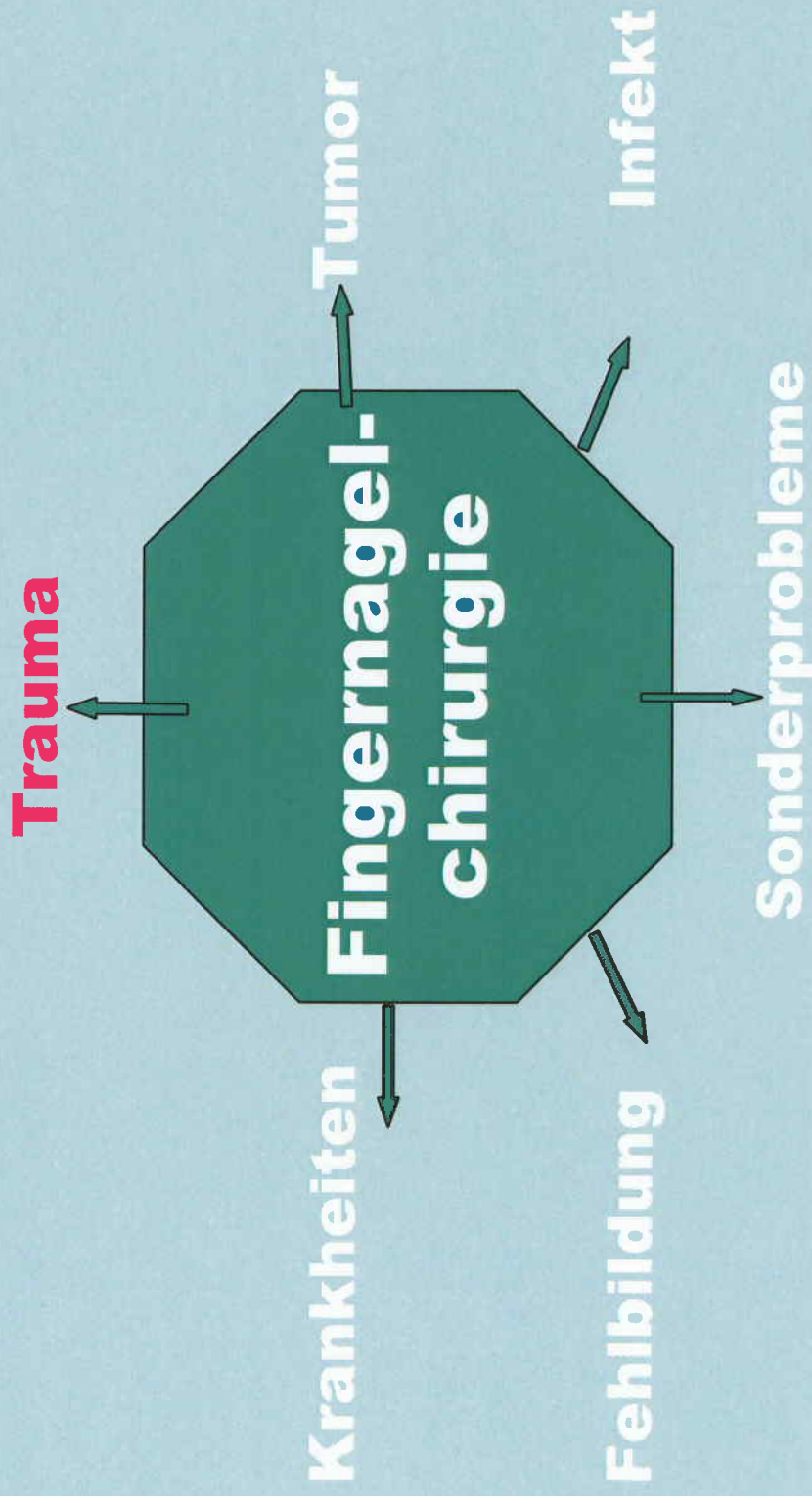


Figure 6. Some of the detailed anatomy of the nail fold is demonstrated. The superficial skin has been incised and folded toward the left. The vasculature between external skin and that skin (with small separation toward the right) lying against the nail plate is shown.





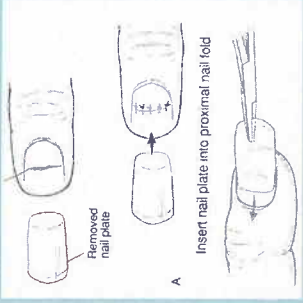
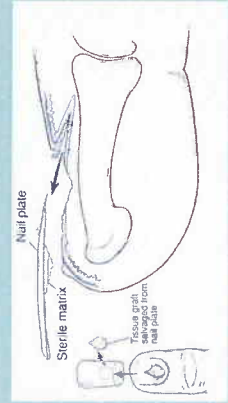
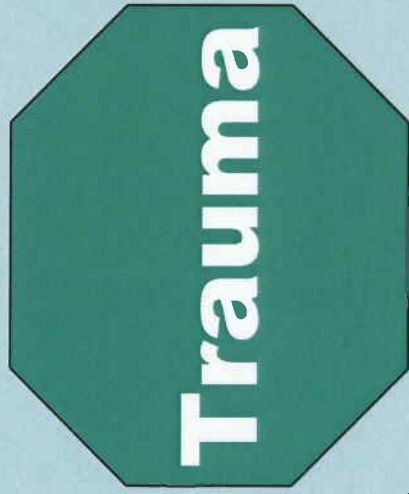
RTZ Nürnberg
Ihr Partner für Gesundheit, Schönheit & Wohlbefinden

Dr. A. Gruber

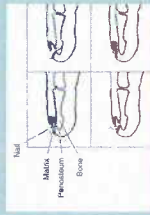


DIAH e.V.

Nagelbettverletzung



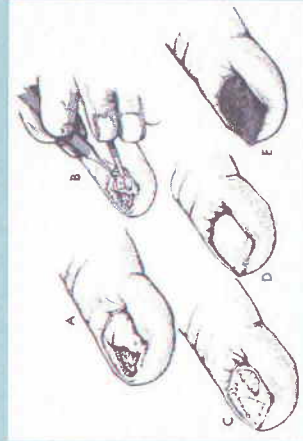
Nagelfrakturen



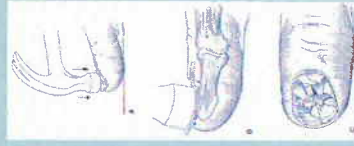
subunguales-Hämatom



Avulsions-Verletzungen



schwere 'Crush' Verletzungen



RTZ Nürnberg
Ihr Partner für Gesundheit, Schönheit & Wohlbefinden

Dr. A. Gruber



DIAH e.V.

